

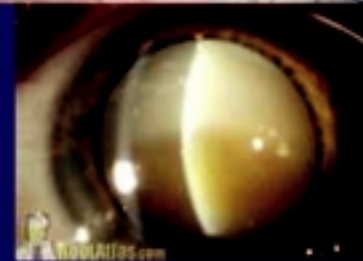
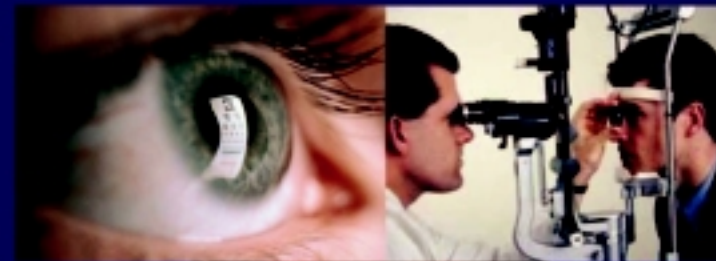Practical



Ophthalmology

A Manual For Medical Students

Dr. Zeina M. Al-Sabti



IRAQ - Baghdad
Mutnbi - St.
(00964) 07702697982
ali_hadi2@yahoo.com



Practical

Ophthalmology

**A Manual For Medical
Students**

By

Dr. Zeina Mohammed Al-Sabti

Ophthalmologist

University of Anbar – College of Medicine

M.B.Ch.B, F.I.B.M.S.

I.C.O.

**Member of European Society For Cataract and Refractive
Surgery**

2011

Practical Ophthalmology
A Manual For Medical Students



Name of Book: Practical Ophthalmology

Authorship: Dr. Zeina Mohammed Al-Sabti

Measur Book: 14.5X25

Number of Pages: 102



Dar
AL-MURTADHA
Publishing

IRAQ • Baghdad

Mutnbi • St.

(00964) 07702697982

ali_hadi2@yahoo.com

No deposit in Library and Archives in Baghdad

2013 Year 1570

Contents

Preface	7
1-Anatomy of the eye	8
2-History	11
3- Visual Acuity Examination	12
4-Anterior Segment Examination	18
5-Tonometry	24
6- Stains	32
7- Examination of the Cornea	38
8- Posterior Segment Examination	45
9-Visual Field Examination	56
10-Refraction	58
11-Laser in Ophthalmology	66
12-Red eye	70
13- Common ocular conditions	73
Index	97

Preface

Practical ophthalmology ; A manual for medical students is intended to help 5th year medical students since they usually have limited ophthalmologic knowledge and clinical capabilities.

Some clinical theory and background information are included to help the medical students understand the practical informations presented.

This manual is not intended to cover everything that needs to be learned by medical students and it is complementary for the lectures delivered to them.

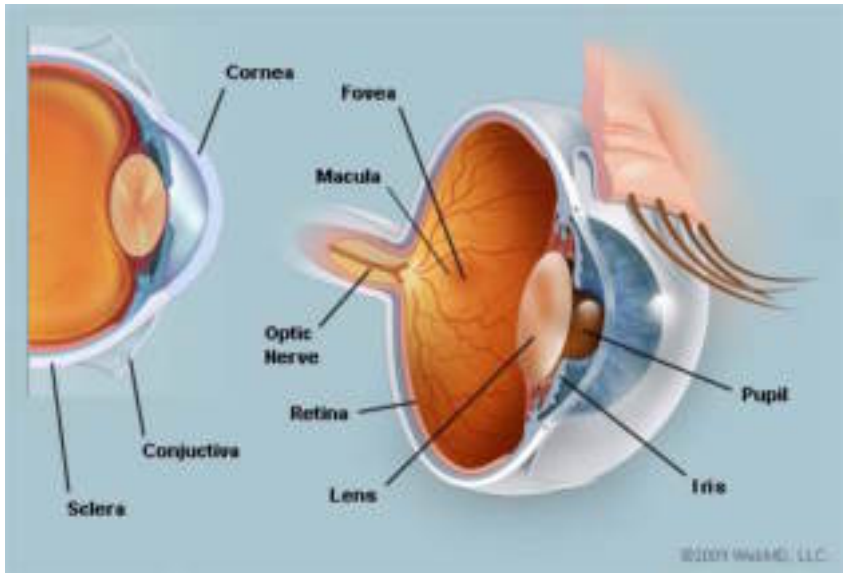
I would like to take this opportunity to offer my heartfelt thanks to my husband Dr.Thakir Mohammed for the willing collaboration and the exceptional initiative he have showing during the writing of this book .

I dedicate this book to my mother for her encourage and support ,and to my son Ahmed and my daughter Najwan.

Dr. Zeina Al-Sabti

2011

Anatomy of the eye



In order to understand the anatomy of the eye ,we divide the eye into two segments :

Anterior and posterior segments

Anterior segment contents:

Eyelid,conjunctiva,anterior part of sclera,cornea, anterior chamber(which containsaqueous humor),iris ,pupil,lens and zonules,posterior chamber, ciliary body,and anterior third of vitreous body.

Posterior segment contents:

Posterior two thirds of the vitreous body, choroid, retina, optic nerve and posterior part of the sclera.

So we have machines that used for examination of anterior segment and those used for examination of the posterior segment.

Extra ocular muscles

1-medial rectus(MR) innervation by third cranial nerve.

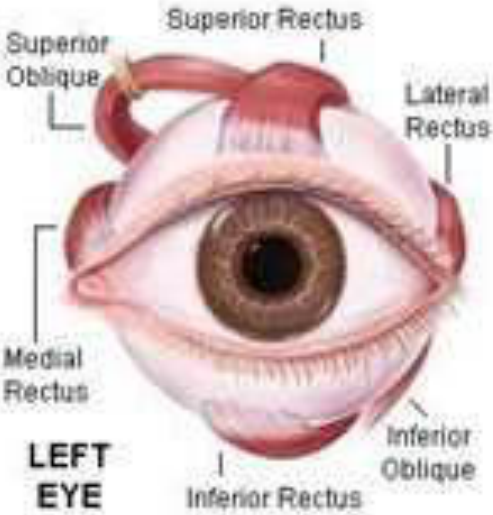
2-lateral rectus (LR) innervation by sixth cranial nerve.

3-superior rectus (SR) innervation by third cranial nerve.

4-inferior rectus(IR) innervation by third cranial nerve.

5-superior oblique(SO) innervation by fourth cranial nerve.

6-inferior oblique(IO) innervation by third cranial nerve.



History

Obtaining a thorough history from the patient is the important first step in an ophthalmic evaluation .In general ,the history includes the following information :

1-Demographic data ,including name ,date of birth,sex,race, and occupation.

2-chief complain and history of present illness.

3-present status of vision and any ocular symptoms.

4-past ocular history, including prior eye diseases, injuries, treatments , surgeriesand ocular medications.

5-past systemic history ,including allergies,adverse reactions to medications, medication use, medical problems and hospitalizations.

6-family history,including poor vision and other familial ocular and systemic diseases.

Visual Acuity examination

Visual acuity (VA) is acuteness or clearness of vision, which is dependent on the sharpness of the retinal focus within the eye and the sensitivity of the interpretative faculty of the brain.

The term visual acuity refers to an angular measurement relating testing distance to the minimal object size resolvable at that distance. Ophthalmologists usually refer to the Snellen acuity as a measure of the resolving ability of the eye.

The primary measurement tool is the letter chart introduced in 1862 by Donders and Snellen at the Eye Infirmary at Utrecht in the Netherlands.

The traditional Snellen chart is printed with eleven lines of block letters. The first line consists of one very large letter, which may be one of several letters, for example E, H, or N. Subsequent rows have increasing numbers of letters that decrease in size. A person taking the test covers one eye, and reads aloud the letters of each row, beginning at the top. The smallest row that can be read accurately indicates the visual acuity in that eye.

	Metric Feet	
A	6/60	20/200
D F	6/36	20/120
H Z P	6/24	20/80
T X U D	6/18	20/60
Z A D N H	6/12	20/40
P N T U H X	6/9	20/30
U A Z N F D T	6/6	20/20
N P H T A F X U	6/5	20/16

The standard chart distance is six meters, normal acuity is designated 6/6, and other acuities are expressed as ratios with a numerator of 6. Many rooms do not have 6 metres available, and either a half size chart subtending the same angles at 3 metres, or a reversed chart projected and viewed by a mirror is used.

For people who have worse than 6/60 vision, a different eye chart can be used that measures beyond 6/60 vision, or, for the most accurate measurements, a Vision Chart can be moved closer to the patient to measure the smallest letter that they can see at a lesser distance(eg,5/60,4/60,3/60 and 2/60). It is common to record vision worse than 2/60 as Count Fingers (CF at one meter distance), Hand

Motion or movement (HM at one meter distance),
Light Perception (LP), or No Light Perception (NLP).

Examination of visual acuity in children

Many methods used for examination of visual acuity
in children like :

Matching pictures



Matching three dimensional figures



Allen picture chart

These figures are used in the chart in varying sizes for assessing visual acuity :



Cardiff acuity test



Sheridan – Gardiner test



Optokinetic drum




Catford



Anterior Segment Examination

Slit-lamp Biomicroscopy



Designed by Alvar Gullstrand at 1911

The slit lamp is a unique instrument that permits magnified examination of transparent or translucent

tissues of the eye in cross-section. The slit lamp enhances the external examination by allowing a binocular, stereoscopic view; a wide range of magnification (10X, 16X and 25.6X and in new generations of slit lamp the magnification is 500X); and illumination of variable shapes and intensities to highlight different aspects of ocular tissue.

Uses of the slit lamp

- 1- Examination of anterior segment of the eye.
- 2- Examination of posterior segment of the eye with added lenses.
- 3- Measurement of intraocular pressure.

Parts of the slit lamp


Viewing Arm



The binocular eyepieces provide stereoscopic vision and can be adjusted to accommodate the examiner's interpupillary distance (Eyepiece available 10 x ,12.5x and 16x)

The focusing ring can be twisted to suit the examiner's refractive error. The magnification element can be adjusted with the side dial, also there is Applanation Tonometer Mount





Illumination Arm



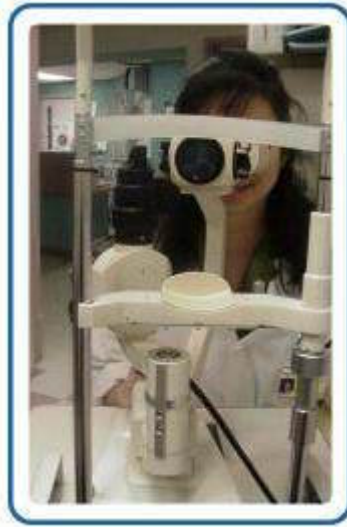This arm contain Lamp, Reflecting Mirror and set of filters. The illumination arm can be swung 180 degrees side to side on its pivoting bases allowing the examiner to direct the light beam anywhere between the nasal and temporal aspect of the eye examination.

The dimension of the light beam can be varied in height and width with these levers(Slit Width Continuous from 0mm to 9mm, and at 9mm, slit becomes circle , while Slit Height 9mm, 8mm, 5mm, 3mm, 2mm, 1mm, 0.2mm). It can provide diffuse or focal illumination as an optical cross-section of the anterior segment.

This arm include filters which are :

	Heat absorbing filter to decrease the heat of light.
	Grey filter to decrease the intensity of light.
	Red free filter which give a green light used for examination of any vitreous opacities or for localization of blood vessels and used with rose Bengal stain.
	Cobalt blue filter which give a blue light used with fluorescein stain.

The Patient Positioning Frame



The patient positioning frame consist of two upright metal rods to which are attached a forehead strap and a chin rest.The chin rest height can be adjusted with the knob just below it.

The Base and Joystick



The joystick allows for focusing by shifting forward, backward, laterally or diagonally. The joystick can also be rotated to lower or elevate the light beam.

Other Attachments:

Various additional devices can be attached to the slit lamp, such as an applanation tonometer for measuring intraocular pressure and Hruby lens for examining the fundus.

Tonometry

Tonometry is the measurement of intraocular pressure (IOP).

IOP is measured in millimeters of mercury (mmHg), the range of normal IOP is between 10 and 21 mmHg and the mean IOP is 16 mmHg.

When the IOP exceeds the normal range (>21 mmHg), this means either **glaucoma** (high IOP + optic disc damage + visual field changes) or **ocular hypertension** (high IOP without optic disc damage or visual field changes).

Note: sometimes there is optic nerve damage and visual field changes in spite of normal IOP, this called **normal tension glaucoma**.

While when the IOP decrease (< 10 mmHg), this mean **ocular hypotony** and the causes of ocular hypotony : corneal wound, scleral wound, choroidal detachment and retinal detachment).

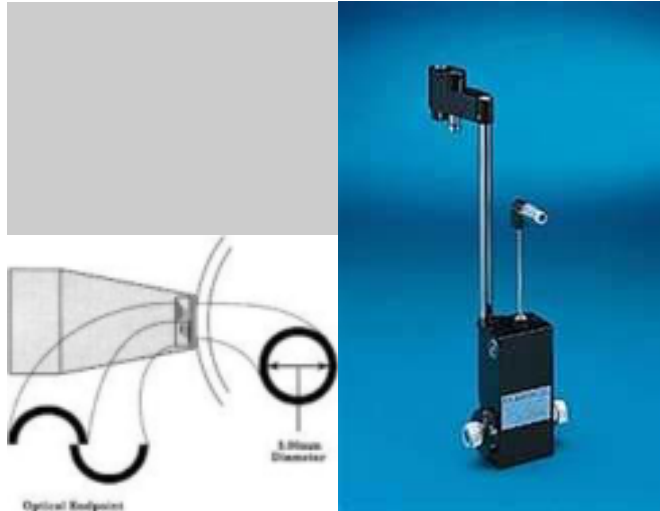
Types of Tonometers

The instruments that used for measurement of IOP can be categorized into two groups based on the way they determine IOP :

- 1- Applanation tonometers:** measure the force needed to flatten, or applanate, a small area of the central cornea. The greater the force needed to applanate a known area of cornea, the higher the IOP.
- 2- Indentation tonometers:** measure the amount of indentation of the cornea produced by a known weight.

Applanation Tonometers

1-The Goldmann Applanation Tonometer



Is the most common and accurate tonometer. Usually mounted on the standard slit lamp. need for topical anesthesia and fluorescein

The principal parts of Goldmanna pplanation tonometer are :

- The tonometer tip, the part of the instrument that contacts the patient's cornea, contains a biprism (two-beam-splitting prisms) that converts a circular area of contact between the tonometer

- A metal rod connects the tonometer tip to the instrument's housing.
- The tonometer housing contains a mechanism that can deliver a measured force, controlled by the force adjustment knob on the housing, to the tonometer tip.
- The force adjustment knob on the housing is used to vary the amount of force needed to applanate the cornea. The scale reading on the knob is multiplied by 10 to express IOP in mmHg.

2-The Perkins Tonometer



is a handheld, portable applanating device. The technique for use, mechanism of action, and relative accuracy are similar to those of the Goldmann Tonometer. It is used for seated or supine patients or in operating room. need for topical anesthesia and fluorescein.

3- The Tonopen



Is a portable electronic applanating device, can be used with a seated or supine patient, and are useful in the presence of corneal scars or edema. need for topical anesthesia only.

4- **The noncontact (air-puff) Tonometer**



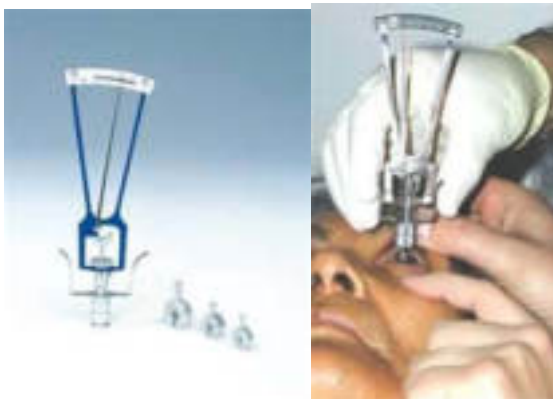Non contact tonometer determines IOP by measuring the time necessary for a given force of air to flatten a given area of the cornea. No need for topical anesthesia or fluorescein.

5- **Pulsairtonometer**, non contact and portable tonometer. No need for fluorescein or anesthesia.



Indentation Tonometer

The Schiottz Tonometer is a portable, easy to use ,frequently used in the operating room and emergency room .The patient must be supine for Schiottz Tonometer, need topical anesthesia.



The principal parts of Schiottz tonometer:

1-A curved metal foot plate is designed for placement upon the patient's cornea.

2-A metal plunger moves up and down inside a cylinder and rests upon the patient's cornea in the center of the foot plate.

3-The instrument's frame is held between the examiner's thumb and forefinger by the handles.

4-A variety of weights are available to place upon the tonometer to provide the indentation force (5.5 g,7.5g,10g, and 15g).The 5.5g weight is used first.

5-A numbered scale on the tip of the instrument shows the measurement of indentation via an indicator needle,which is moved by a hammer in response to the amount of corneal indentation produced by the weight.The scale reading on the instrument must be converted to mmHg using a printed Schiottz conversion table,which is supplied with the instrument.

Note :all types of tonometer are of contact type(contact with the cornea) except air puff and pulsairtonometers.

Stains

Stains (dyes) instilled into the tear film can facilitate examination of the ocular surface by highlighting ,and making more evident,certain pathologic changes.we have two stains:

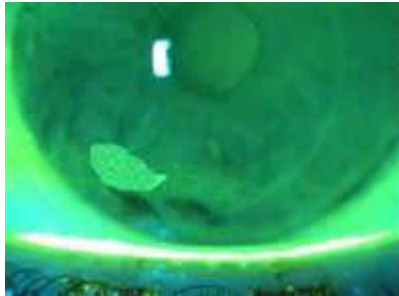
1- Fluorescein stain




available as paper strips, it does not stain corneal or conjunctival epithelium but readily enters and stain the stroma in areas in which epithelium is absent (or even in areas in which epithelial cells have loose intercellular junctions),the color of fluorescein is orange and when use the cobalt blue filter of the slit lamp ,the blue light causes the dye to fluoresce a bright green color.

Uses of fluorescein:

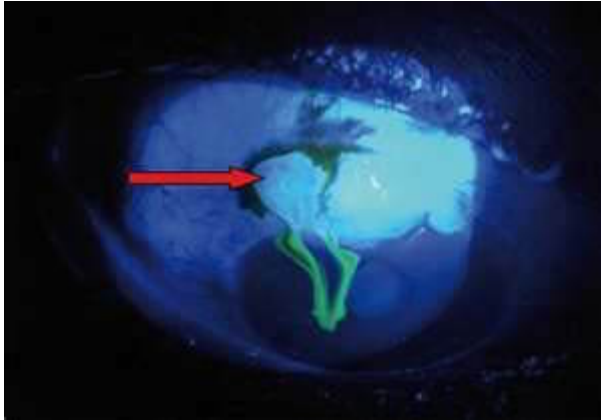
1-detection of any epithelial defect ,like :
corneal abrasion ,recurrent corneal erosion,
corneal ulcer and viral dendritic ulcer



2- Measurement of IOP

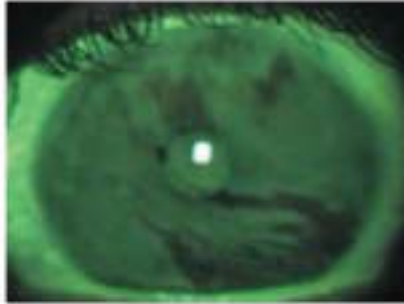


3- Detection of corneal perforation or wound leak (Seidel test).



4- Measuring Tear film breakup time in dry eye. Applying fluorescein dye to the ocular surface, examine the patient with slit lamp through the cobalt-blue filter and measuring the time between the last blink and the appearance of the first dry spot provides information about the adequacy of the supply of tears.

The normal breakup time (BUT) is at least 10 seconds.



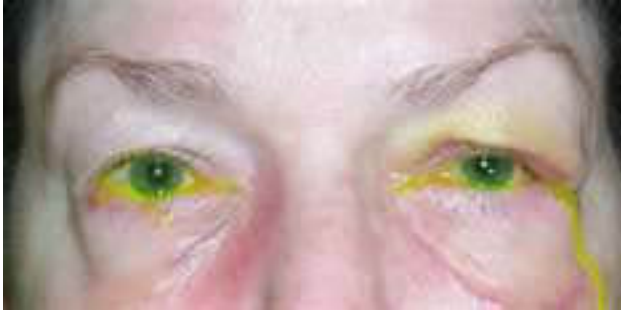Tear break-up time (above) and tear break-up pattern (below) should be used and studied along with a red-thread and tear meniscus measure.



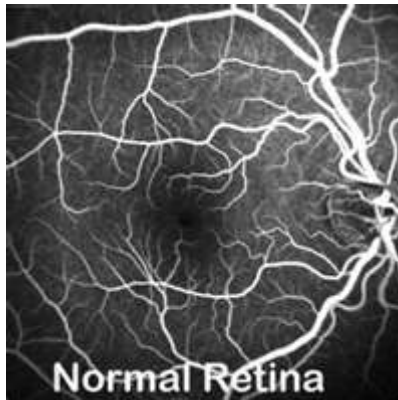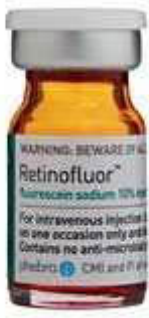5- Fluorescein disappearance test for evaluation of the patency of the lacrimal passage. Instill fluorescein into both eyes, wait 5 minutes, use a cobalt-blue light to examine the tear meniscus:

a- the tear film should be clear, indicating complete disappearance of fluorescein dye.

b- if the tears are still tinged yellow, the lacrimal outflow system has functional or anatomic blockage.



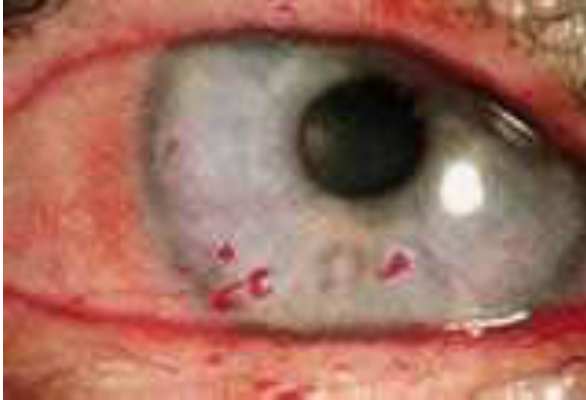Note: fluorescein also available in vial form and given intravenously and called fluorescein angiography and is used to evaluate diseases of the retina,retinal pigment epithelium and choroid.



Rose Bengal




Unlike fluorescein ,rose Bengal stains abnormal and devitalized epithelial cells,it also stain mucus and keratin,(so fluorescein remains extracellular while rose Bengal stains dead and degenerating cells and mucus).It is used in dry eye examination.The color of this stain is red and best observed using red –free filter and the stained areas are red with either green or white light.



picture show corneal filaments stained with rose bengal stain

Examination of the cornea

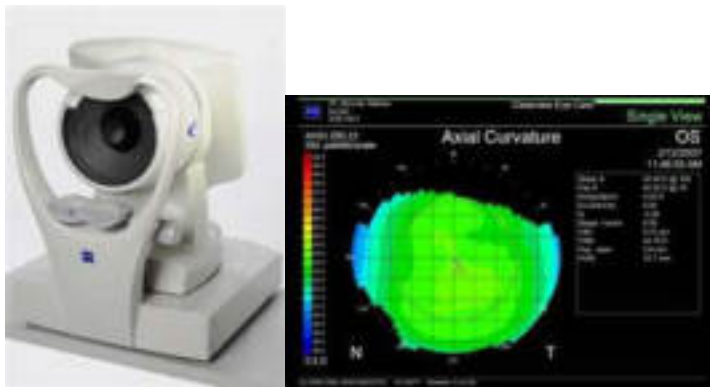
Placido disc



The hand held Placido Disc is the easiest and most practical device for assessing corneal topography, used for examining the front surface of the cornea. It

consists of a pattern of alternately black and white concentric rings reflected by the cornea and seen through a convex lens mounted in an aperture at the center of the pattern. The rings are illuminated using a light situated behind and adjacent to the patient's head. Any eccentricities in these ring images is caused by irregularities in the topography of the cornea itself. Such an instrument gives a qualitative evaluation of large corneal astigmatism, and is useful in cases of irregular astigmatism as in keratoconus.

Topography



Also known as videokeratography, corneal topography is a process for mapping the surface curvature of the cornea, similar to making a contour map of land ,(It provides a color-coded map of the corneal surface).The dioptric powers of the steepest

and flattest meridian and their axes are also calculated and displayed.

Using computerized imaging technology, the 3-dimensional map produced by the corneal topographer aids an ophthalmologist in the diagnosis, monitoring, and treatment of various visual conditions.

The corneal topographer is made up of a computer linked to a lighted bowl that contains a pattern of concentric rings. The patient is seated in front of the bowl with his or her head pressed against a bar while a series of data points are generated on a placido disk, which has been projected on the cornea. Computer software digitizes these data points to produce a printout of the corneal shape, using different colors to identify different elevations.

The procedure itself is painless and brief. It is a noncontact examination that photographs the surface of the eye using ordinary light. The greatest advantage of corneal topography is its ability to detect conditions invisible to most conventional testing.

Indications of topography:

- To diagnose early keratoconus (because diagnosis of early or subclinical keratoconus is difficult, while advanced keratoconus is easy to diagnose).
- Planning refractive surgery .
- To evaluate postoperative changes in corneal shape after refractive surgery.
- Pre Corneal transplants.
- To evaluate Corneal scars , opacities and Corneal deformities
- Pre Fitting contact lenses.
- To quantify Irregular astigmatism following corneal transplantation.
- To evaluate acquired astigmatism after cataract extraction .

Pachymetry



Corneal pachymetry is a simple, painless test and noninvasive ultrasonic technique for measuring corneal thickness, and has been used primarily in the evaluation of persons with corneal diseases and in the assessment of persons at risk for glaucoma.

The thickness of the cornea is greatest at the limbus, where it ranges from 0.7 to 0.9 mm. Normal central corneal thickness is 0.49 – 0.56 mm .

Ultrasonic corneal pachymetry is performed by placing an ultrasonic probe on the central cornea,

after the cornea has been anesthetized with a topical anesthetic. A technician can operate the pachymeter and it normally takes less than 30 seconds per eye to complete measurements.

Uses of corneal pachymetry:

1- is particularly essential prior to a LASIK procedure for ensuring sufficient corneal thickness to prevent abnormal bulging out of the cornea, a side effect known as ectasia.


2-is considered an important test in the early detection of glaucoma.

3-it may be useful in assessing candidates for penetrating keratoplasty (corneal transplant), and assessing graft failure and the need for regrafting in corneal transplant recipients by aiding in the early diagnosis and treatment of graft rejection.

1- it may also be useful in assessing the response to treatment of corneal transplant rejection.

2- Corneal pachymetry has also been used to assess progression of disease in patients with certain corneal dystrophies and degenerative diseases.

Specular microscopy



Involves photography of the corneal endothelium and subsequent analysis of cellular characteristics such as shape, density and distribution. The normal endothelial cell is a regular hexagon. The normal cell density is about 3000 cells per mm^2 ; counts of below 1000 mm^2 are associated with significant risk of endothelial decompensation.

Posterior Segment Examination

Instruments for examination of posterior segment:

- 1- Slit lamp with added lenses
- 2- Direct ophthalmoscope.
- 3- Indirect ophthalmoscope.
- 4- Imaging studies ,these include fundus camera, angiography and ultrasonography.

Lenses that used with slit lamp for examination of posterior segment of the eye; we have 3 types of added lenses that used with slit lamp for examination of the posterior segment of the eye:

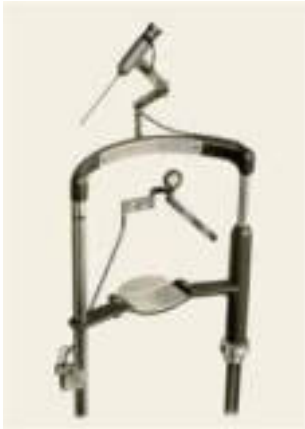1- Plus lenses



available in two powers +78Diopter and +90Diopter,both gives inverted real image ,but

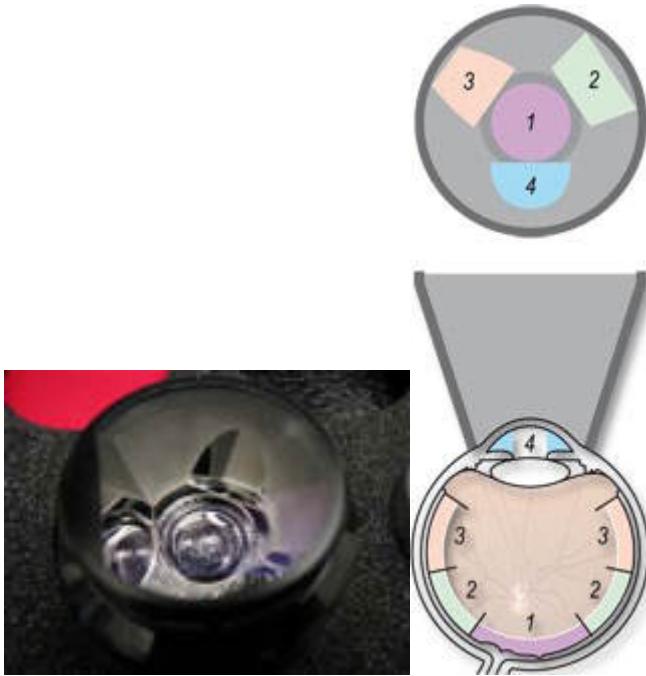
the magnification of the +78D is 10X and its field of view is 30 degree, while the magnification of the +90D is 7.5X and the field is 40 degree.

2- Hruby lens



which is a planoconcave lens with a power - 55D or -58.6 Diopter. It gives an erect virtual image, the magnification is 12X and its field of view is 10 degrees. It is attached to the slit lamp.

3- Goldmann-Three mirror contact lens



Ocular's Classic Goldmann Lens has three mirrors angled at 59, 67, and 73 degrees to permit viewing of the fundus and anterior chamber. It is a contact lens ,so need lubricant agent such as methylcellulose between it and patient's cornea.

This figure describes the lens and the three mirror function:

1- the lens in the center(concave lens),is not a mirror and it affords a view of the posterior pole of the fundus(Lens examination of the ocular fundus in the 30° zone).Magnification 10X and its field of view 20 degree and the image is erect virtual.

2- This mirror is for midperipheral fundus . Mirror with a declination of 73° Observation of the zone outside of the 30° range

3- this mirror used for viewing the peripheral fundus(Mirror with a declination of 67° Observation of the peripheral sections of the ocular fundus, and under favourable conditions, also of the oraserrata).

4-the dome shape mirror permits examination of the angle of the anterior chamber and the area of the ciliary body(Mirror with a declination of 59° Observation of the vitreous body and ocular fundus sections neighboring the oraserrata as well as a gonioscopic examination).








Direct ophthalmoscope

Designed by Hermann Von Helmholtz at 1850

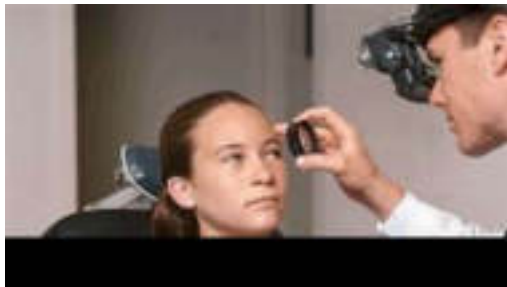

Use right hand of the examiner and the right eye of the examiner for examination of the patient's right eye and left hand ,left examiner eye for examination of the patient's left eye.

illumination Opening of the direct Ophthalmoscope

	Full spot: viewing through a large pupil.
	Medium size spot: viewing through mid-dilated pupil.
	Small spot: viewing through a small pupil.
	Red-free filter: help in detecting changes in the nerve fiber layer and identifying micro aneurysms and other vascular anomalies.
	Slit :evaluating retinal contour.
	Reticule or grid: measuring vessel caliber or diameter of a small retinal lesion.
	Fixation target: identifying central or eccentric fixation.

Indirect ophthalmoscope



Examine the fundus indirectly through a variety of convex, handheld magnifying

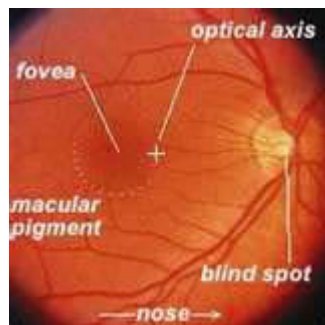
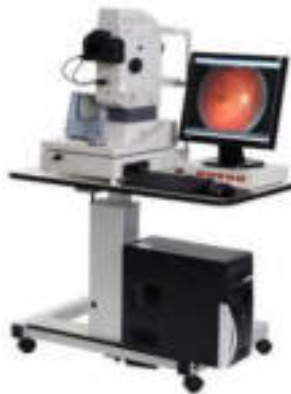condensing diagnostic lenses close to the patient eye .Condensing lenses commonly used in indirect ophthalmoscopy are +13,+14D ,+16,+20,+22 and+30D|

Comparison between direct and indirect ophthalmoscope

	Direct ophthalmoscope	Indirect ophthalmoscope
1	Uniocular(one eye used forexamination)	Binocular(both eyesused for examination)
2	two dimensional picture	three dimensional picture perception of depth stereopsis
3	erect image	inverted image
4	virtual image	real image
5	magnification 15X	3 to 5 X (according to the power of the condensing lens used)
6	Field of view 5 degree	40 to 50 degree (according to the power of the condensing lens used)
7	contain corrective lenses (because it affected by RefractiveErrors of patient and examiner)	no corrective lenses (not affected by Refractive Errors of patient and examiner)

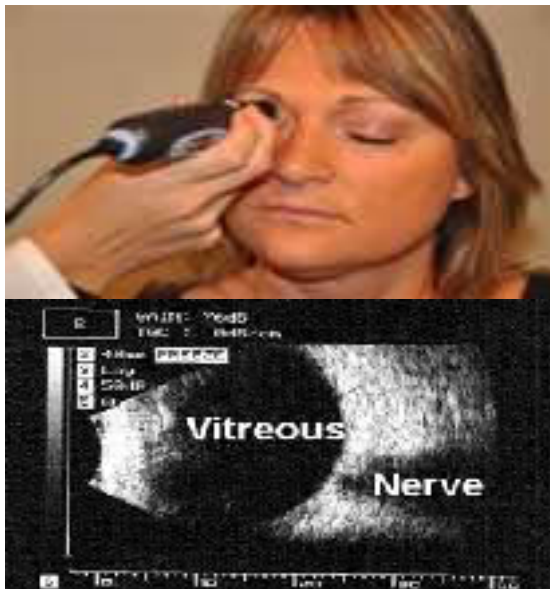8	examine the fundus directly	use with condensing lens
9	no need for dilatation of the pupil of patient	need for dilatation of the pupil of patient
10	small and portable and Battery - powered	need electricity
11	used for examination of anterior segment of eye	used only for posterior segment examination
12	no teaching mirror	contain teaching mirror
13	not used during surgery	used during surgery

Photography



help to document abnormalities of the fundus,also called fundus camera ,its magnification 2.5X and the field of view 30 degree and give erect virtual image.

Ultrasonography



Diagnostic ultrasonography is a useful technique when media opacification prevents adequate ophthalmoscopy of the posterior segment.Two forms are available : an A-scan is a one-dimensional display used to characterize tissues and used for

measurement the power of the intraocular lens before cataract surgery (biometry), and B-scan is a two-dimensional display used for architectural information.

B-scan is often performed through the eyelids using methylcellulose as a coupling gel.

B-scan used when there is opacity in the eye that prevent visualization of the posterior segment of the eye (eg, corneal opacity and mature cataract) and it is useful for detection :

1-any vitreous opacities (eg, vitritis , endophthalmitis and vitreous hemorrhage).

2- Intraocular foreign body.

3-Retinal detachment .

4-Choroidal detachment.

5-retinal fibrosis and signs of proliferative vitreoretinopathy .

6-any congenital anomalies of the vitreous and retina.

7-intraocular tumors(eg,retinoblastoma).

8-thickening of the posterior sclera and fluid in tenon space (T sign) in severe posterior scleritis.

Visual field examination

The visual field is an inverted and reversed map of corresponding retinal points. The visual field of each eye is tested separately.

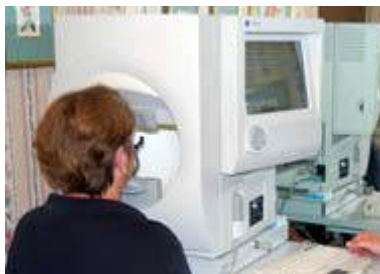A scotoma, also called a visual field defect, is a place in the visual field where an object cannot be seen. A relative scotoma is an area in the visual field where test objects of low luminance cannot be seen, but larger or brighter ones can.

An absolute scotoma is an area where no test object can be seen (eg, the physiologic blind spot or a scotoma in advanced disease). In addition to its density, a scotoma is described by its shape (eg, hemianopia, quadrantanopia, etc) and its location (eg, temporal, superonasal, etc).

Perimeter: is the measurement of the visual field during central fixation using either moving objects (kinetic perimetry, eg, Goldmann perimeter)



or stationary test stimuli (static perimetry, eg, Automated perimeter which test visual field defects by using fixed light location)



Refraction

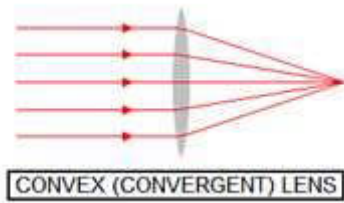
Refraction is the process by which the patient is guided through the use of a variety of lenses so as to achieve the best possible acuity on distance and near vision tests. Refraction involves both objective and subjective measurements. The objective portion of the process of refraction is called retinoscopy and can be accomplished by manual or automated methods. The measurements obtained by retinoscopy can be refined by subjective methods to achieve a final prescription for eyeglasses or other optical aids.

Types of lenses

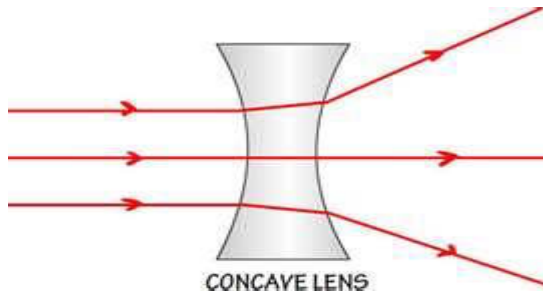
Lenses may be spheres, cylinders, or spherocylinders.

A spherical lens has the same curvature over its entire surface, and thus the same refractive power in all meridians.

Convex spherical lenses converge light rays and are called plus lenses.



Concave spherical lenses diverge light rays and are called minus lenses.



Cylindrical lenses have vergence power in only one meridian, the one perpendicular to the axis of the cylinder. They have no power in the meridian parallel to the axis.



cylinder

Refractive States of the eye

In the normal eye ,parallel light rays are focused sharply on the retina, a condition known as emmetropia. When eye is unable to bring parallel light rays from distance object into focus, the condition is referred to as ametropia.The three basic conditions that may produce ametropiaare :

1-**Myopia (nearsightedness)**,myopic eye has excessive convergent power ;the light rays focus anterior to the retina and a minus (divergent) lens is used to correct myopia.

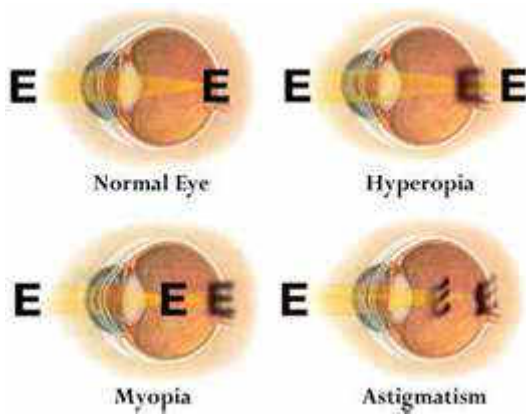
2- **Hyperopia (farsightedness, alsocalled hypermetropia),**

hyperopic eye has insufficient convergence power to focus light rays on the retina; the rays focus posterior to the retina and a plus lens is used to correct hyperopia.

3-**Astigmatism**, the cornea (and sometimes the lens) may not have the same radius of curvature in all meridians. Aberration of the corneal or lenticular surfaces that produces differing radii of curvature is called

astigmatism , and a cylindrical lens is used to neutralize astigmatism.

In most patients, the axis of plus cylinder needed to correct the astigmatism is either close to 90(with-the-rule astigmatism)or close to 180 (against-the-rule astigmatism).In clinical practice, many myopic patients and hyperopic patients also have astigmatism. Aspherocylindrical lens is used to correct myopic and hyperopic astigmatism.



Presbyopia

Is a progressive loss of accommodative ability of the lens caused by the natural process of aging(occur after 40 years).

It generally evidences itself as difficulty with near visual work, such as reading.

Presbyopia occurs in the presence of myopia , hyperopia , and astigmatism. It can be remedied optically with plus lenses.



Retinoscope

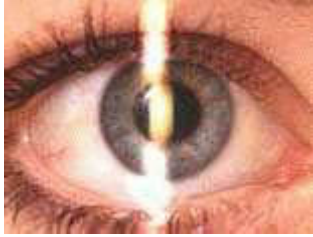

The goal of retinoscopy (objective refraction) is to determine the nature of the patient's refractive error and the approximate lens power that will diminish (neutralize) that error and approach clear vision. In the process of refinement (subjective refraction), the examiner further and exactly determines the patient's final refractive correction by presenting various lenses to the patient until the patient responds that a best and balanced.

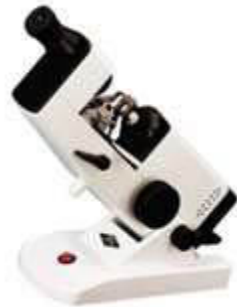

Trial case and trial frame

Retinoscopy, the retina is illuminated through the pupil. The examiner observes the optical phenomena in the patient's pupil while moving the light source.



Lensometry

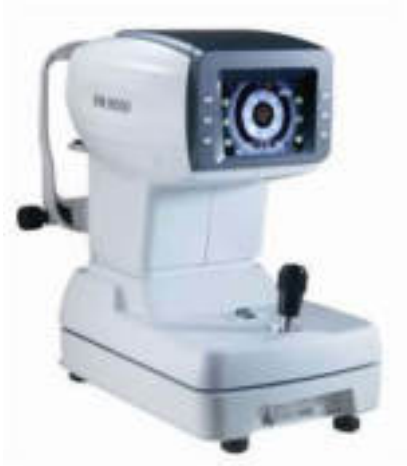

Lensometry is a procedure used to measure the prescription of a patient's present spectacle lenses. Lensometry is performed with an instrument called a lensometer, or lensmeter. Both manual and automated lensometers are available.

Lensometry measures four principal properties of spectacle lenses:

- 1-Spherical and cylindrical power
- 2-Cylindrical axes if cylinder is present
- 3-Presence and orientation of prism
- 4-Optical centration

Automated Refractometry



The method measures refraction automatically with the aid of light – sensitive detectors and a computer until a focused image appears on the retina.

Laser in ophthalmology

Laser mean :light amplification by stimulated emission of radiation.

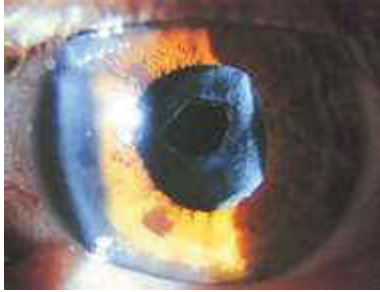Nd:YAG laser



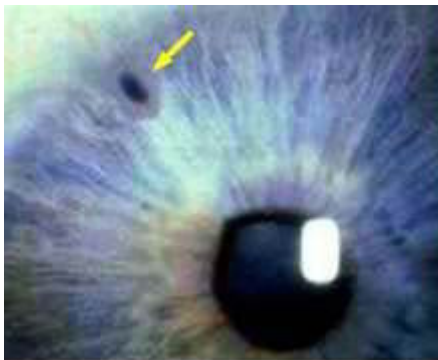
Mechanism of action :photo destruction

Indications of YAG laser in ophthalmology :

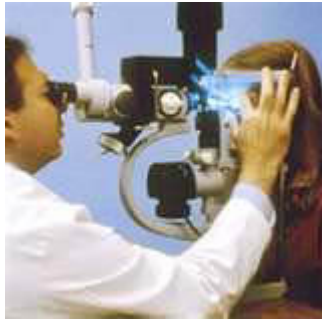(1)-**Posterior capsulotomy**:Creation of an opening in the posterior capsule thickening or opacification which is the most common late complication of uncomplicated cataract surgery .



(2)-**Nd:YAG laser iridotomy**:the purpose of peripheral laser iridotomy is to re-establish communication between the posterior and anterior chamber by making an opening in the peripheral iris. Laseriridotomy is effective in about 75 % of eyes with acute angle-closure glaucoma.



Argon laser



Mechanism of action : photocoagulation

Indication : 1- diabetic retinopathy

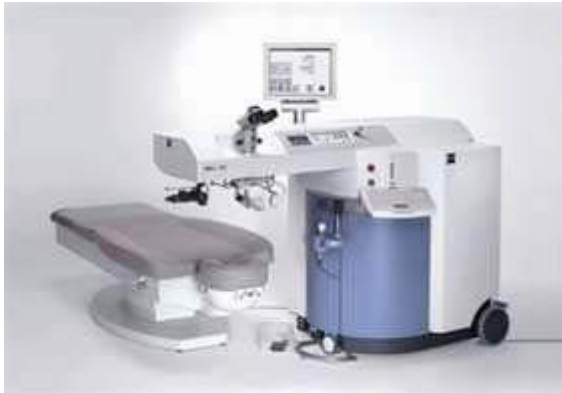2- hypertensive retinopathy

3- some intra ocular tumors

4- prophylactic treatment for retinal degenerations in high myopia

5-retinal vascular diseases

Excimer laser

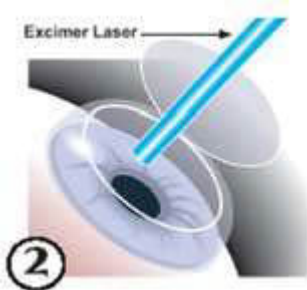


Mechanism of action :photoablation

Indication: for correction of refractive errors (myopia, hypermetropia and astigmatism)

LASIK (laser assisted in situ keratomileusis)

PRK(Photorefractive keratectomy)



Red eye

There are many possible causes of a red eye or eyes. Some are cause for concern, some are medical emergencies. Others are of no consequence or concern at all. The degree of redness or appearance of blood usually does not correlate to how serious the situation is. It is generally more important whether you also have eye pain or impaired vision.

Common Causes

Bloodshot eyes appear red because the vessels in the surface of the white portion of the eye (sclera) become enlarged and irritated. This may result from extremely dry air, sun exposure, dust, foreign body, an allergic reaction, infection, trauma, or other conditions.

- One common cause of a red eye is straining or coughing. This can lead to a bright red, uniformly dense bloody area on the sclera. This is called a **subconjunctival hemorrhage**. Although this bloody area may appear alarming, it is a fairly common occurrence and of little significance. If you notice a bloody blotch in one eye that doesn't hurt, but just

looks bad, don't worry. It generally clears up on its own within two weeks or three.

- **Eye infections or inflammation** can occur in different locations. They cause redness as well as possible itching, discharge, pain, or vision problems.
- **Blepharitis** : inflammation of the eyelash follicles along the eyelid. It is caused by skin bacteria. Itching is common and your eyelids may appear greasy or crusty.
- **Bacterial orbital cellulitis** : is a life-threatening infection of the soft tissues behind the orbital septum. It can occur at any age but is more common in children
- **Conjunctivitis** : inflammation or infection of the membrane that lines the eyelids and coats the surface of the eye (the conjunctiva). This condition is often referred to as "pink eye". It may be caused by a virus, bacteria, allergy, or irritation. If caused by an organism, this is highly contagious.
- **Corneal ulcers**: often caused by a bacterial or viral infection.
- **Uveitis** : inflammation of the uvea, which includes the iris, ciliary body, and choroid. This is often related to an autoimmune disorder,

infection, or exposure to toxins. Often, only the iris is inflamed, which is called iritis.

- **Endophthalmitis** :implies inflammation ,often purulent ,involving all intraocular tissues except the sclera.
- **Episcleritis and scleritis**

Other potential causes include:

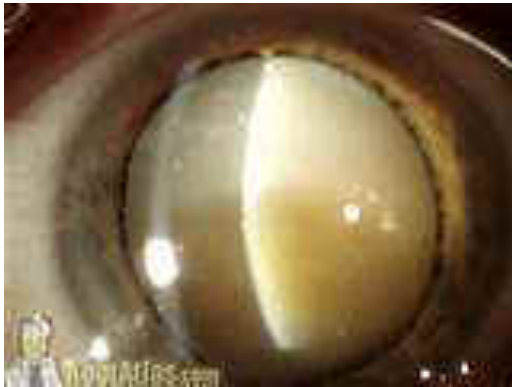- **Cold or allergies.**
- **Foreign objects** in the eye .
- **Acute glaucoma:** a sudden increase in eye pressure that is extremely painful and causes serious visual disturbances. This is a medical emergency. Most times, glaucoma is chronic and gradual.
- **Corneal scratches** caused by sand, dust, or overuse of contacts.
- **Bleeding problems**(for example, from excess use of anticoagulant drugs).

Common ocular problems

Cataract

A cataract is any opacity in the lens. The term cataract comes from the Greek word katarraktes (down-rushing; waterfall)

mature cataract



vision in patient with cataract

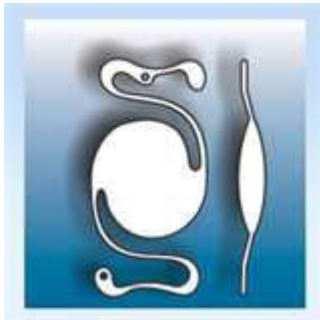

Treatment of cataract is only surgical ; cataract extraction with intraocular lens implantation(IOL).We have two types of IOL,

Posterior chamber IOL

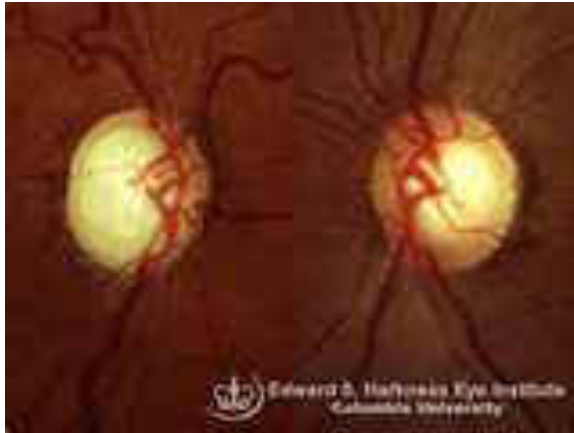

Anterior chamber IOL



Glaucoma

Glaucoma : pathological changes in optic nerve head ,visual field defect and often, but not always associated with increased intraocular pressure.

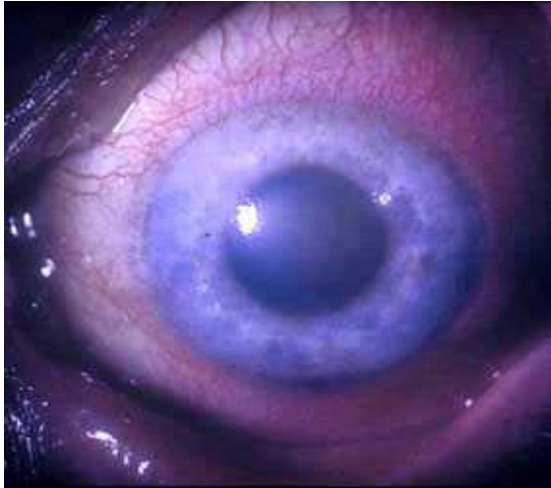

Optic disc cupping



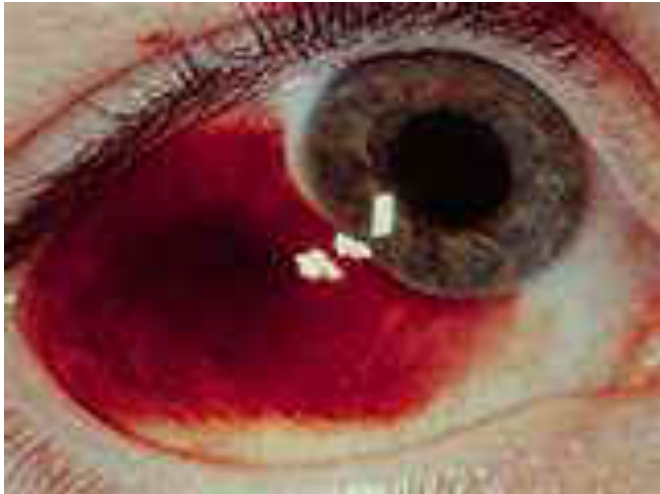Constriction of visual field

Acute angle closure glaucoma (corneal edema, ciliary injection and dilated pupil)

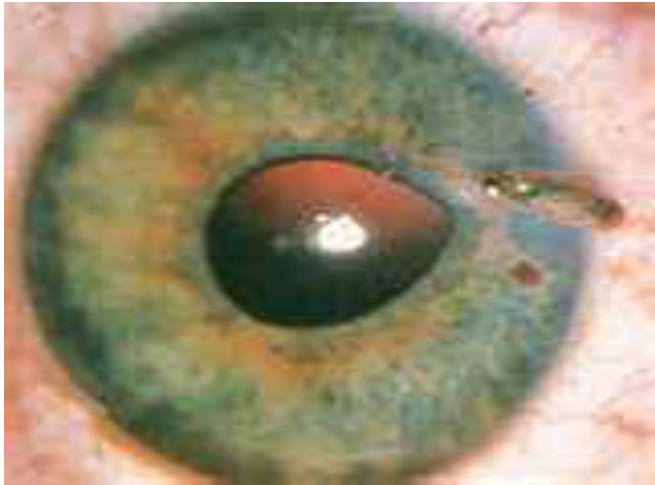

Trauma

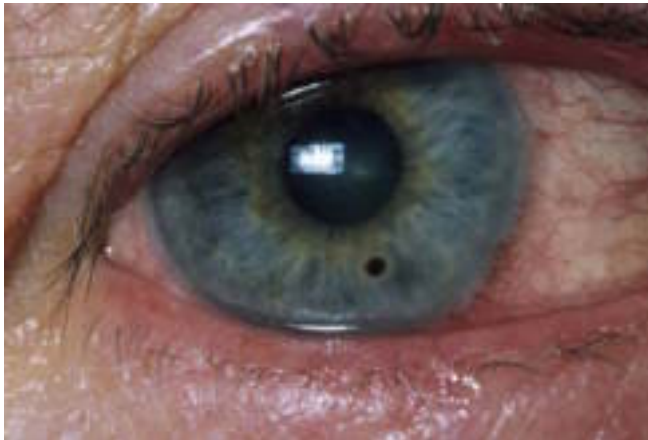
Subconjunctival hemorrhage



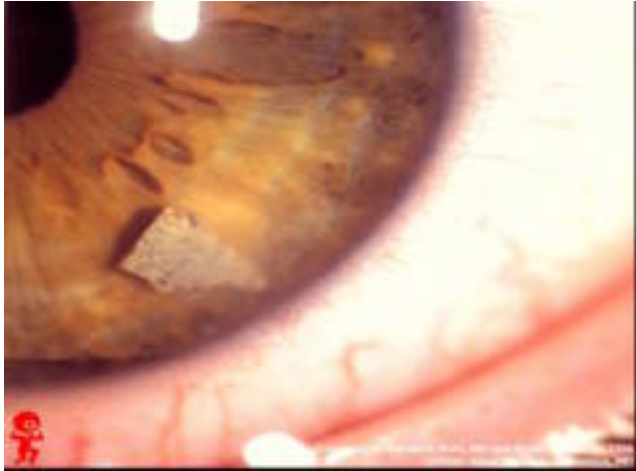Corneal wound with iris prolapse



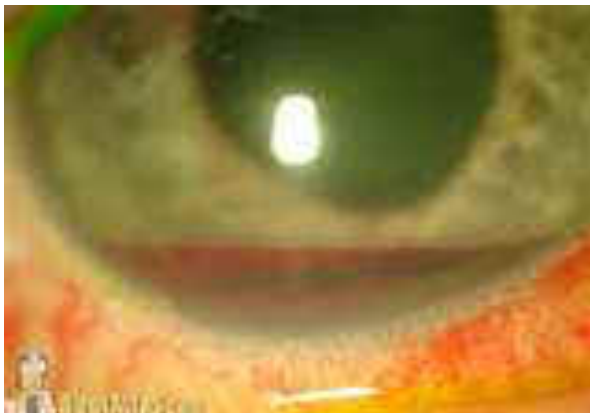Corneal foreign body



Foreign body in the anterior chamber



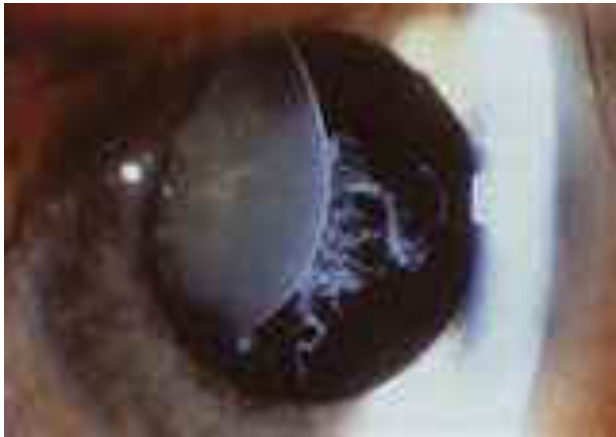Hyphema (blood in the anterior chamber)



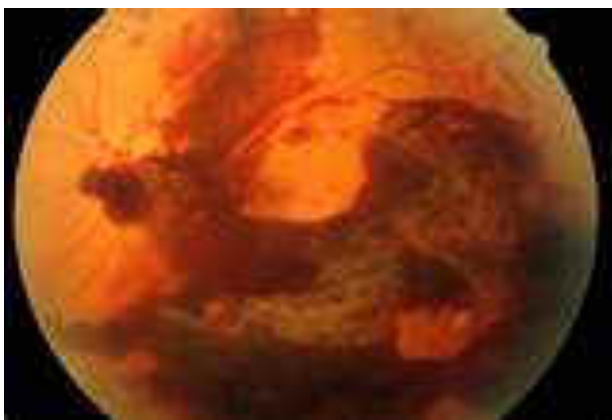iriddialysis



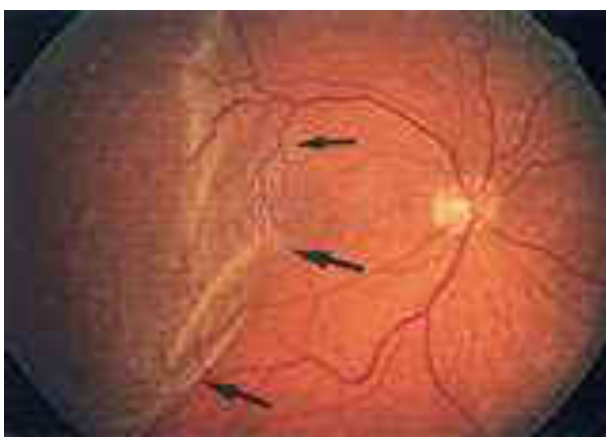
Dislocated lens



Vitreous hemorrhage

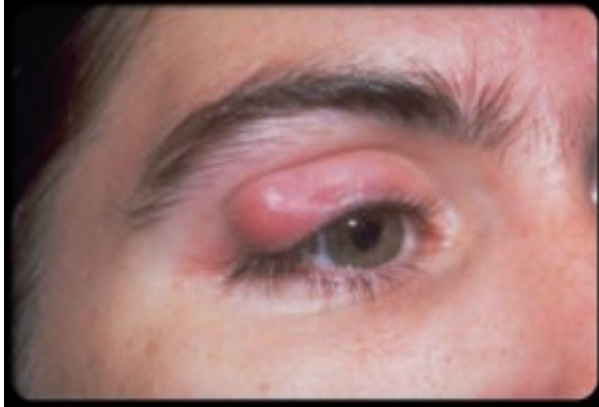

Retinal detachment

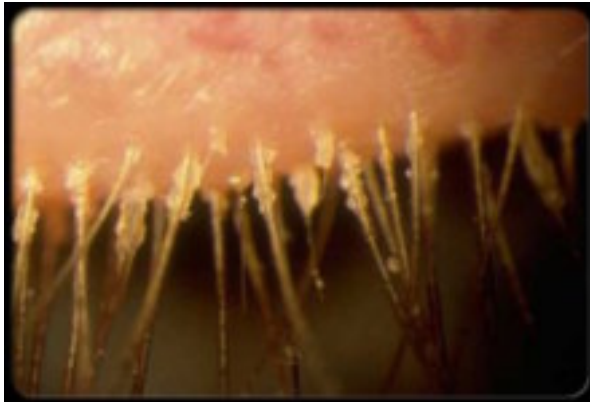


Infection and inflammation

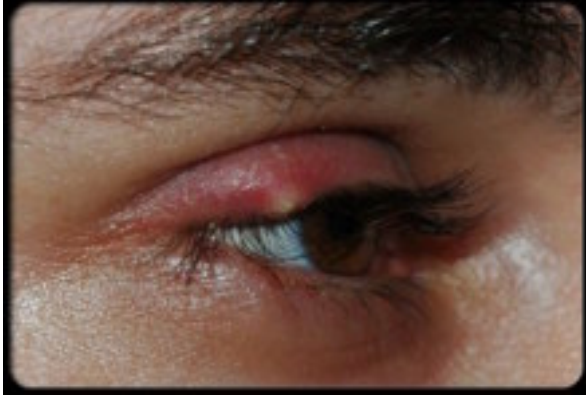Chalazion



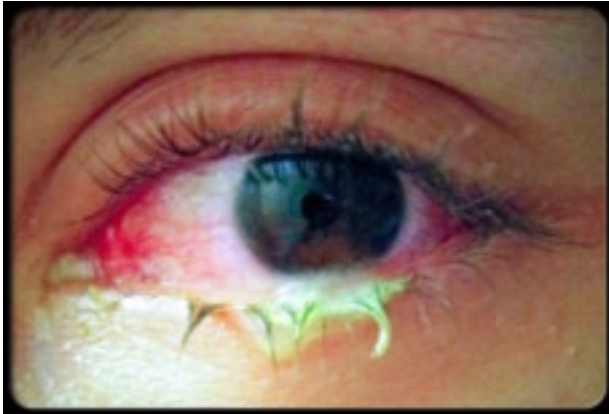Blepharitis



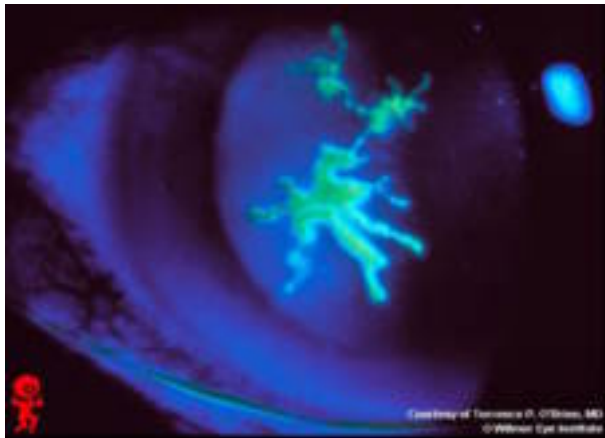
Sty



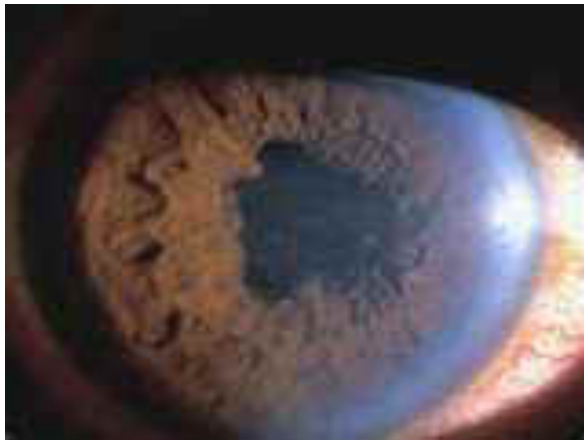Conjunctivitis



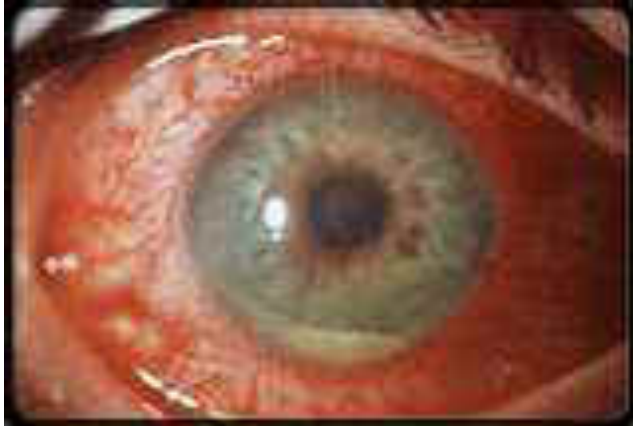Dendritic viral corneal ulcer



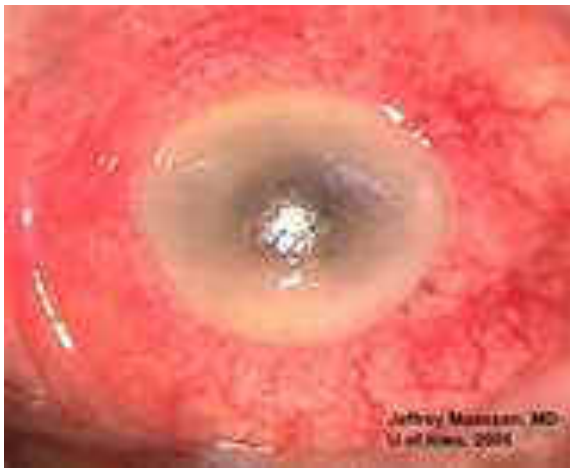Uveitis(posterior synechia)



Hypopyon(pus in the anterior chamber)



endophthalmitis



Refractive errors



Myopia



Hypermetropia



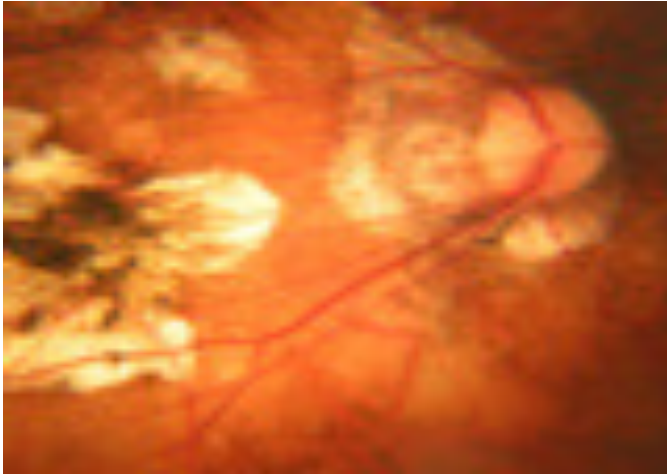
Astigmatism



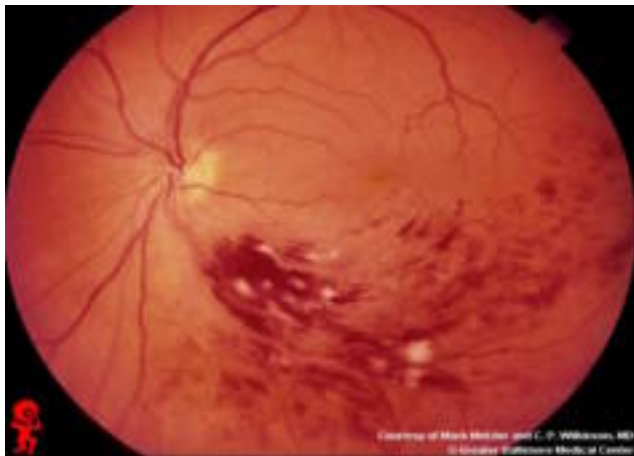presbyopia

Retina

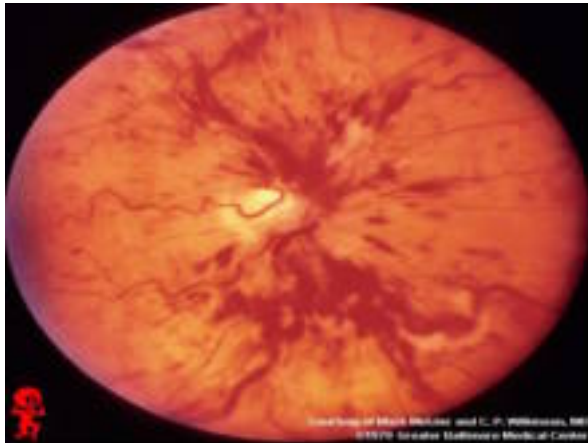myopic degeneration



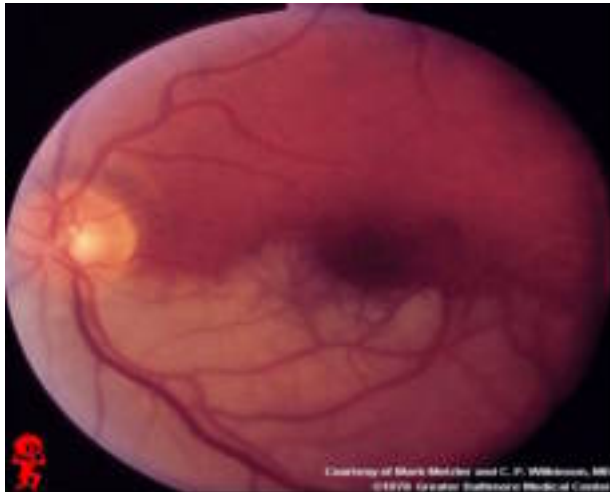Branch retinal vein occlusion



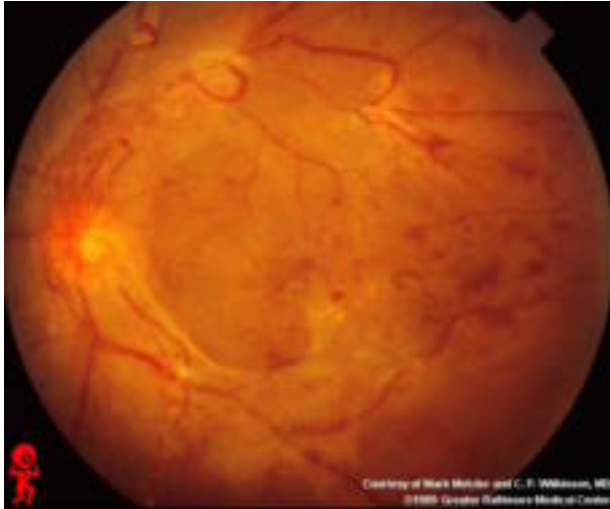
Central retinal vein occlusion



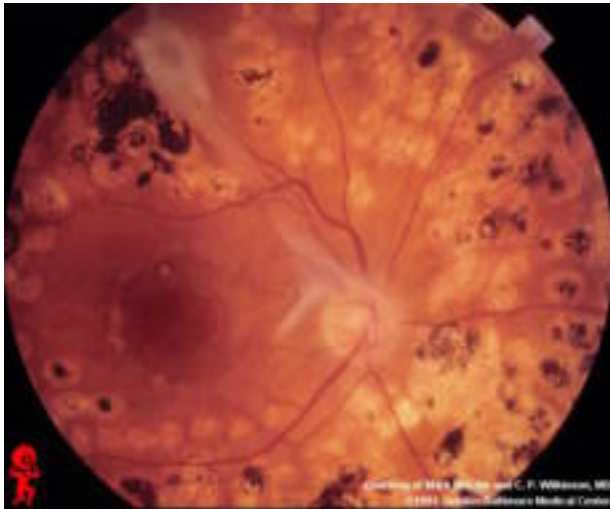
branch retinal artery occlusion



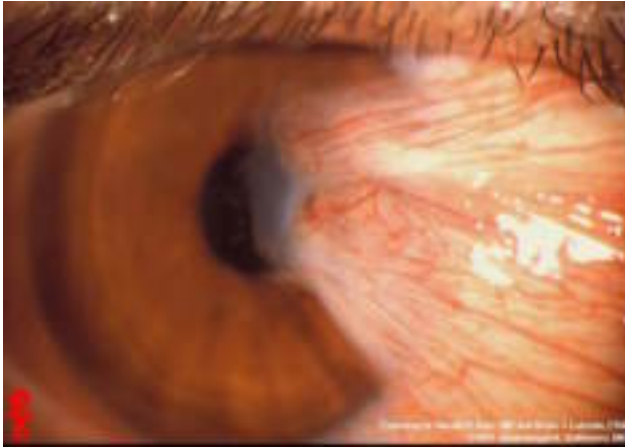proliferative diabetic retinopathy



argon laser photocoagulation



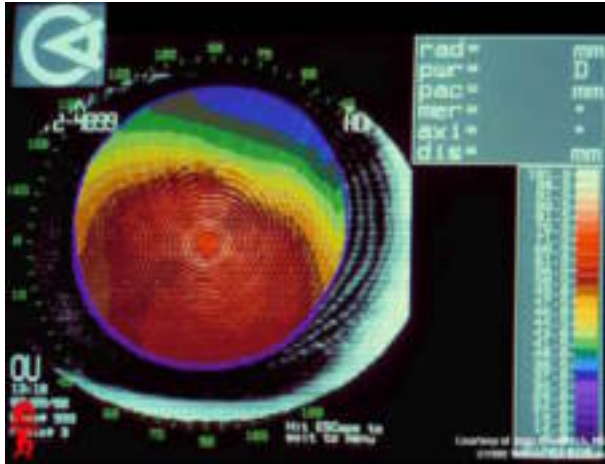
Miscellaneous conditions



Pterygium




Keratoconus
topography of keratocouns




Normal vision



Vision in Keratoconus



Floaters



Normal

Both eyes aligned with object

Squint

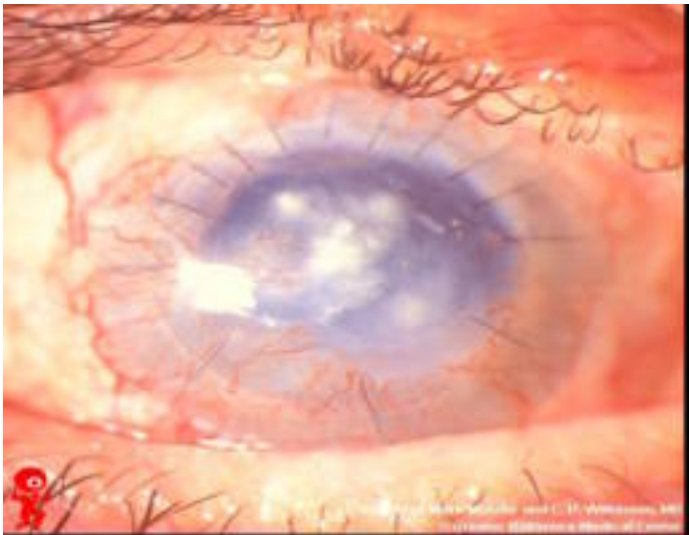
One eye not aligned with object

Squint

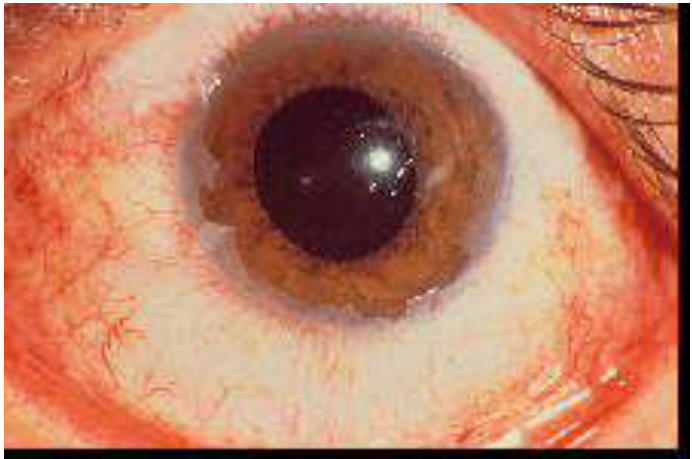
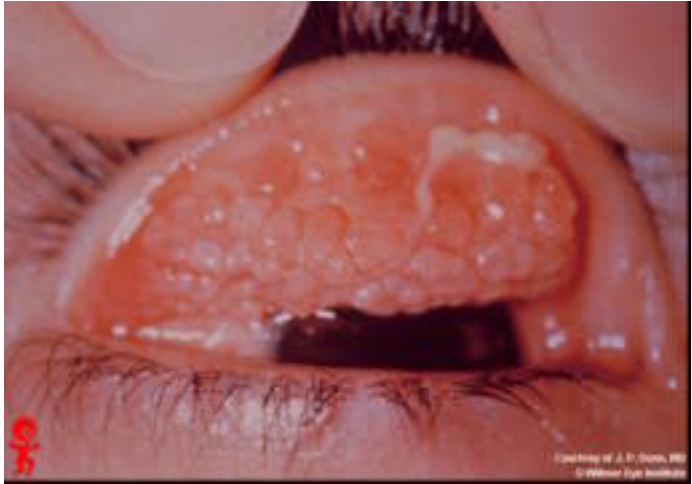
Squint

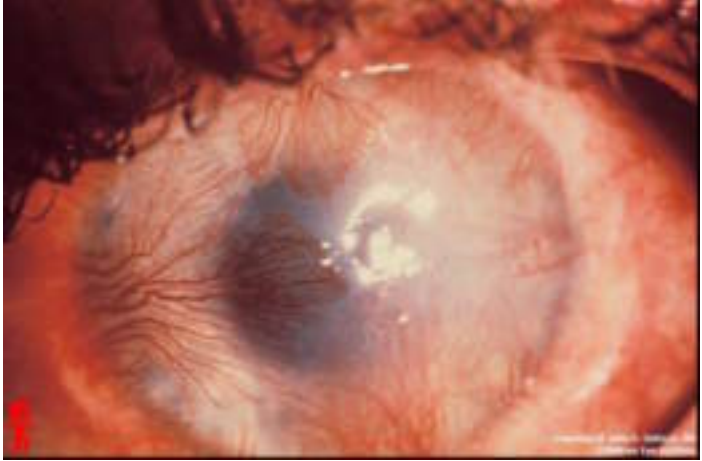
corneal graft rejection



papillae in allergic conjunctivitis

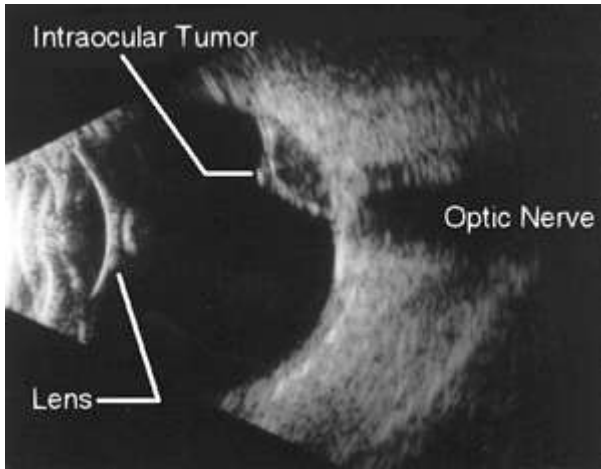


acid burn

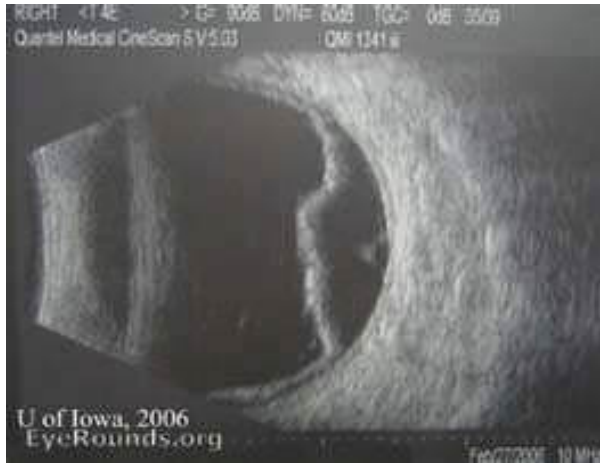

alkali burn

B-scan shows intraocular tumor



B-scan shows retinal detachment



Index

A

- Abrasion ,corneal,17
- Absolute scotoma,31
- Accommodation,34
- Acid burn,56,
- Acuity examination,4
- Acute angle closure glaucoma,44
- Acute conjunctivitis,48
- Against –the –rule astigmatism,33
- Air-puff tonometers,14
- Alkali burns,57
- Allergic conjunctivitis,56
- Anesthetic agents,13
- Angiography,19

Anterior chamber,1
Anterior chamber angle,26
Anterior segment examination,8
Anterior chamber IOL,43
Applanation tonometry,12
Aqueous humor,1
Argon laser,38
A-scan echography,30
Astigmatism,33,51

B

Biomicroscope,8
Blue filter ,10
Branch retinal artery occlusion,52
Branch retinal vein occlusion,52
B-scan echography,30

C

Cameras,fundus,29
Capsulotomy,laser,37
Cataract,42
Central retinal vein occlusion,52
Chalazion,47
Children,V.A. testing,5
Cobalt – blue filter,10
Concave lenses,32
Condensing lenses,28
Conjunctiva,1
Conjunctivits,48
Convex lenses,32
Cornea,21
Cylindrical lenses,32

D

Diabetic retinopathy,53
Direct ophthalmoscope,27
Dry eye,18

E

Endophthalmitis,50
Eximer laser,38
Extraocular muscles,2
Eyeglasses,34

F

Field of vision,31
Filters,9,10
Finger counting,5
Floaters,55
Fluorescein,17
Fluorescing Angiography,19
Foreign body,45
Fundus camera,29

G

Glaucoma,12
Goldmannapplanation tonometer,12
Goldmann three mirror lens,26

H

Hand movement,5
Herpes simplex,49
History taking,3
Hruby lens,25

Hypermetropia,33,50

Hyphema,46

Hypopyon,49

Hypotony,12

I

Illumination arm,9

Indirect ophthalmoscope,28

Inflammation,47

IOP,12

Iridotomy,laser,37

K

Keratoconus,54

Keratometers

L

Laser,37

Lens ,42

Lensometry,35

M

Minus lenses,32

Mucus,20

Myopia,33,49

O

Objective kinetic drum,7

Optic disc cupping,43

P

Pachymeter,233
Papillae,56
Perimetry,31
Peripheral fundus,26
Perkins tonometer,14
Picture charts,6
Placido disc,21
Plus lenses,32
Posterior segment examination,25
Posterior synechiae,49
Presbyopia,34
Prisms,13
Pulsair tonometer,15

R

Red eye,40
Refraction,32
Refractometry,36
Refractive errors,33
Retinoscope,34
Rose Bengal,20

S

Schiotz tonometer,15
Scotoma,31
Seidel test,18
Specular microcopy,24
Slit lamp,8
Snellen acuity chart,4
Stains,17
Styes,48

T

Tonometry,12
Tonopen,14
Topography,21
Trauma,44
Trial frames,35
Trial lenses,35

U

Ultrasonography,30
Uveitis,49

V

Viewing arm,9
Visual acuity,4
Visual field,31
Vitreous Hemorrhage,47